

Case Report

Open Access

Renal cell carcinoma metastasizing to duodenum: a rare occurrence

Alka Bhatia*¹, Ashim Das¹, Yashwant Kumar¹ and Rakesh Kochhar²

Address: ¹Department of Histopathology, Postgraduate Institute of Medical Education and Research, Chandigarh, India and ²Department of Gastroenterology, Postgraduate Institute of Medical Education and Research, Chandigarh, India

Email: Alka Bhatia* - yashwantk74@yahoo.com; Ashim Das - ashim126@gmail.com; Yashwant Kumar - ykabh@hotmail.com; Rakesh Kochhar - rkochhar@yahoo.co.in

* Corresponding author

Published: 14 September 2006

Received: 28 August 2006

Diagnostic Pathology 2006, 1:29 doi:10.1186/1746-1596-1-29

Accepted: 14 September 2006

This article is available from: <http://www.diagnosticpathology.org/content/1/1/29>

© 2006 Bhatia et al; licensee BioMed Central Ltd.

This is an Open Access article distributed under the terms of the Creative Commons Attribution License (<http://creativecommons.org/licenses/by/2.0>), which permits unrestricted use, distribution, and reproduction in any medium, provided the original work is properly cited.

Abstract

Background: Duodenal metastasis is rare in renal cell carcinoma (RCC) and early detection, especially in case of a solitary mass, helps in planning further therapy.

Case presentation: We present the case report of a 55 year old male with duodenal metastasis of RCC. This patient presented with jaundice and abdominal lump one year after nephrectomy. On upper gastrointestinal endoscopy a submucosal mass lesion was noted in the duodenum, the biopsy of which revealed metastasis.

Conclusion: In a nephrectomized patient presenting with jaundice and an abdominal mass, the possibility of metastasis should be suspected and a complete evaluation, especially endoscopic examination followed by biopsy, should be carried out.

Background

Renal cell carcinoma (RCC) has a potential to metastasize to almost any site. In descending order of frequency, the most common sites of metastasis are the lung, lymph nodes, liver, bone, adrenal glands, kidney, brain, heart, spleen, intestine, and skin [1]. It can involve any part of the bowel and accounts for 7.1% of all metastatic tumours to small intestine [2]. Duodenal metastasis from RCC is very uncommon and only few cases have been described in the English literature (table 1) [3-18]. Also duodenal metastasis generally occurs when there is widespread nodal and visceral involvement and evidence of metastatic disease elsewhere in the body. Here we present the case report of a patient with duodenal and liver metastasis who presented with jaundice and right sided abdominal lump one year after nephrectomy. Duodenal biopsy performed revealed metastasis in the duodenum.

Report of a case

The patient was a 55 years old male who came to gastroenterology out patient department with complaints of jaundice and an abdominal mass. He had a history of RCC in the left kidney and had undergone left radical nephrectomy one year ago in our institute. The tumour was present in the lower pole and measured 7 × 5 × 6 cm. Microscopically, it was a conventional clear cell carcinoma (Furhman grade III) involving the renal sinus with tumour emboli in the renal vein. The adrenal gland and ureter were free. This time the patient had jaundice and an abdominal lump. An upper gastrointestinal endoscopy (UGIE) followed by duodenal biopsy was performed. Endoscopy showed a 4 × 4 cm submucosal mass lesion (Fig. 1) in the second part of duodenum. A biopsy was taken from the mass and sent for histopathology.

Table 1: Previously reported examples of duodenal metastasis in patients with renal cell carcinoma

Author	Year	Age/Sex	Duration post-nephrectomy	Presenting symptoms	Other organs involved	Treatment	Patient outcome
Lawson et al [3]	1966	69/F	0 years	Bleeding anemia	-	Pancreatico-duodenectomy	Alive (8 months FU)
Tolia et al [4]	1975	-/M	16 years	-	-	-	5 months
Heymann et al [5]	1978	64/M	8 years	Bleeding	Colon	Complex procedure	3 weeks
McNichols et al [6]	1981	52/M	10 years	Malabsorption	-	Diagnostic only	-
Lynch et al [7]	1987	16/M	1 year	Bleeding	-	Embolization	Alive (6 months FU)
Robertson et al [8]	1990	61/M	6 years	Jaundice	-	Embolization	6 months
		67/M	2 years	Bleeding	Lungs	-	Lost to FU
		70/M	13 years	Bleeding	Pancreas	Whipple procedure	-
						Duodenectomy	-
Gastaca et al [9]	1996	-	8 years	-	-	Metastatectomy	Alive (6 months FU)
Toh et al [10]	1996	59/F	10 years	Obstruction anemia	-	Embolization-local resection	-
Ohmura et al [11]	2000	62/M	5 years	Obstruction	-	PPPD	-
Hashimoto et al [12]	2001	57/M	11 years	Bleeding	Pancreas	Gastrojejunostomy	7 days
Nabi et al [13]	2001	40/M	4 years	Obstruction	-	Duodenectomy	Alive (4 years FU)
Sawh et al [14]	2002	53/M	6 years	Bleeding	Brain Anal canal	Radiotherapy	Alive
Loualidi et al [15]	2004	76/M	5 years	Anemia	-	Metastatectomy	-
Chang et al [16]	2004	63/F	9 years	Bleeding	-	Intestinal Resection	9 months
George et al [16]	2004	65/M	2 years	Obstruction	Omentum ileum	-	-
Arroyo [17]	2005	-	-	-	-	-	-
Bhatia et al (current)	2006	50/M	1 year	Jaundice	Liver	Diagnostic only	Lost to FU

PPPD = Pylorus preserving pancreatico-duodenectomy, FU = Follow up

The biopsy consisted of three fragments which revealed duodenal mucosa with normal villi, however many of the vascular channels in the lamina propria showed tumour emboli. The tumour cells were mildly pleomorphic, had abundant pink cytoplasm and low nuclear:cytoplasmic ratio (Fig. 2). These were positive for cytokeratin (CK), vimentin (Vim) and epithelial membrane antigen immunostaining and negative for chromogranin (Fig. 3). The surrounding lamina propria, villi and crypts were normal. Considering these features, a diagnosis of metastatic renal cell carcinoma was offered on the biopsy. This was followed by abdominal Ultrasonography (USG), CT scan, liver function tests and other investigations to know the extent of illness. Liver enzymes were raised significantly with serum alkaline phosphatase levels of > 1000 IU/L. Both USG and CT scan showed multiple tumour deposits in the liver. Other visceral organs and peritoneum were normal. Radiotherapy as a part of palliative treatment was planned but could not be performed as the patient was lost to follow up.

Discussion

Small bowel involvement by metastatic tumors is rare and has been reported in only 2% of autopsy cases [2]. Com-

mon metastatic malignancies known to involve the small bowel are melanomas, lung cancer, carcinoma of the cervix, RCC, thyroid carcinoma, hepatoma and merkel cell carcinoma. Males are more commonly affected (male: female = 1.5:1) and the incidence of metastasis increases with age [17]. Metastatic lesions of the duodenum are most frequently located in the periampullary region or the duodenal bulb [17]. On endoscopy the lesion can be seen as a submucosal mass with ulceration of the tip, multiple nodules of varying sizes or raised plaques [19]. In the present case the metastatic lesion was seen as a 4 × 4 cm submucosal mass in the 2nd part of duodenum. The patients commonly present with gastrointestinal bleeding or intestinal obstruction [10,17], however our patient presented with jaundice and abdominal lump. On investigation he was found to have liver metastasis also.

The majority of patients are found to have metastasis within a year after nephrectomy though it can be seen even after several years [16]. The routes of spread can be (i) peritoneal dissemination, (ii) direct spread from an intra-abdominal malignancy, (iii) hematogenous and (iv) lymphatic spread [17]. The last two mechanisms can be responsible for metastases in the case reported.

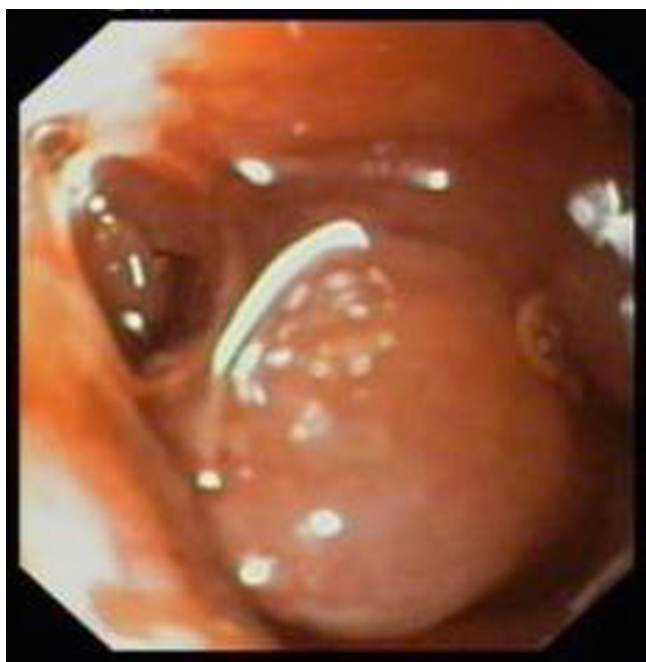

Figure 1
Endoscopic view of submucosal mass lesion in second part of duodenum, with normal glistening mucosa.

Treatment options in a case of RCC metastasis depend upon the extent and location of the lesion. In the majority of reported cases of duodenal metastasis, metastatectomy was done. However for disseminated malignancy like in our case treatment is in the form of palliative (non-curative) surgery, radiotherapy, chemotherapy (Sunitinib) or immune stimulating agents (Interleukin-2). However

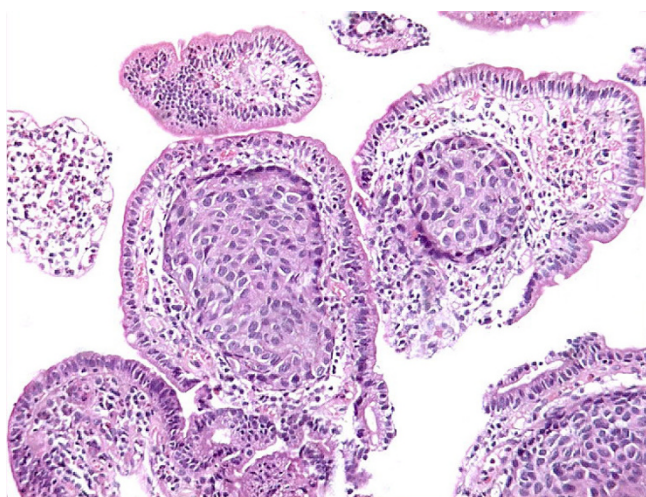


Figure 2
Tumour emboli of renal cell carcinoma in lymphatics of lamina propria.

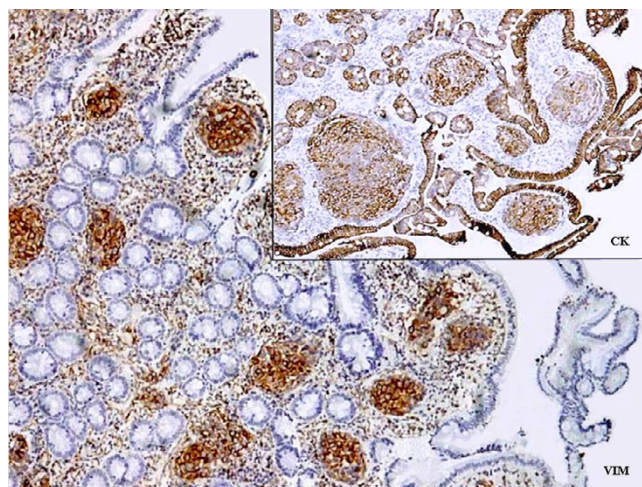


Figure 3
Strong positivity of tumour cells for vimentin and cytokeratin immunostaining.

even after treatment the patients with metastatic disease have poor survival. The average survival is about 4 months and only 10% of these survive for one year [20].

The report therefore highlights the importance of investigating patients of RCC presenting with any gastro-intestinal tract manifestations for metastasis. A complete evaluation, especially endoscopic examination and biopsy, should be carried out in such patients. Awareness of this entity and a high index of suspicion on the part of the treating physician and pathologist would help in proper diagnosis and treatment.

References

1. Murphy WM, Beckwith JB, Farrow GM: **Tumors of the Kidney, Bladder, and Related Urinary Structures.** In *Atlas of Tumor Pathology; 3rd series, fascicle 11* Washington, DC: Armed Forces Institute of Pathology; 1994:128.
2. Willis RA: **Secondary tumors of the intestines.** In *The Spread of Tumours in the Human Body* 3rd edition. London, England: Butterworth & Co Ltd; 1973:209-15.
3. Lawson LJ, Holt LP, Rooke HWP: **Recurrent duodenal hemorrhage from renal cell carcinoma.** *Br J Urol* 1966, **38**:133-137.
4. Tolia BM, Whitmore WF: **Solitary metastasis from renal cell carcinoma.** *J Urol* 1975, **114**:836-838.
5. Heymann AD, Vieta JO: **Recurrent Renal Carcinoma Causing Intestinal Hemorrhage.** *Am J Gastroenterol* 1978, **69**(5):582-5.
6. McNichols DW, Segura JW, De Weerd JH: **Renal cell carcinoma in long-term survival and late recurrence.** *J Urol* 1981, **126**:17-23.
7. Lynch-Nyhan A, Fishman EK, Kadir S: **Diagnosis and management of massive gastrointestinal bleeding owing to duodenal metastasis from renal cell carcinoma.** *J Urol* 1987, **138**(3):611-3.
8. Robertson GS, Gertler SL: **Late Presentation of Metastatic Renal Cell Carcinoma as a Bleeding Ampullary Mass.** *Gastrointest Endosc* 1990, **36**:304-6.
9. Gastaca Mateo MA, Ortiz de Urbina Lopez J, Diaz Aguirregoitia J, Martinez Fernandez G, Campo Hiriart M, Echevarria Garcia-San Frechoso A: **Duodenal metastasis of renal cell adenocarcinoma.** *Rev Esp Enferm Dig* 1996, **88**(5):361-3.

10. SK Toh, JE Hale: **Late presentation of a solitary metastasis of renal cell carcinoma as an obstructive duodenal mass.** *Postgrad Med J* 1996, **72**:178-79.
11. Ohmura Y, Ohta T, Doihara H, Shimizu N: **Local recurrence of renal cell carcinoma causing massive gastrointestinal bleeding: a report of two patients who underwent surgical resection.** *Jap J Clin Oncol* 2000, **30**:241-5.
12. Hashimoto M, Miura M, Matruda M, Watanabe G: **Concomitant Duodenal and Pancreatic Metastases from Renal Cell Carcinoma: Report of a Case.** *Surg Today* 2001, **31**:180-3.
13. Nabi G, Gandhi G, Dogra PN: **Diagnosis and management of duodenal obstruction due to renal cell carcinoma.** *Trop Gastroenterol* 2001, **22**(1):47-9.
14. Ravindranauth N, Joanna Borkowski, Russell Broaddus: **Metastatic Renal Cell Carcinoma Presenting as a Hemorrhoid.** *Arch Path Lab Med* 2002, **126**(7):856-58.
15. Loualidi A, Spooren PF, Grubben MJ, Blomjous CE, Goey SH: **Duodenal Metastasis: An Uncommon Cause of Occult Small Intestinal Bleeding.** *Neth J Med* 2004, **62**:201-5.
16. Chang WT, Chai CY, Lee KT: **Unusual upper gastrointestinal bleeding due to late metastasis from renal cell carcinoma: a case report.** *Kaohsiung J Med Sci* 2004, **20**(3):137-41.
17. Pavlakakis GM, Sakorafas GH, Anagnostopoulos GK: **Intestinal Metastases from Renal cell carcinoma: A Rare Cause of Intestinal obstruction and Bleeding.** *Mt Sinai J Med* 2004, **71**(2):127-30.
18. Arroyo C, Palacios P, Uribe N, Barrera M, Feria G: **[Uncommon metastases in renal carcinoma].** *Gac Med Mex* 2005, **141**(6):543-6.
19. Hsu CC, Chen JJ, Changchein CS: **Endoscopic features of metastatic tumours in upper gastrointestinal tract.** *Endoscopy* 1996, **28**:249-53.
20. Yuvaraja BT, Mahantshetty U, Chamarajanagar RS, Raibhattanavar SG, Tongaonkar HB: **Management of renal cell carcinoma with solitary metastasis.** *World J Surg Oncol* 2005, **3**:48.

Publish with **BioMed Central** and every scientist can read your work free of charge

"BioMed Central will be the most significant development for disseminating the results of biomedical research in our lifetime."

Sir Paul Nurse, Cancer Research UK

Your research papers will be:

- available free of charge to the entire biomedical community
- peer reviewed and published immediately upon acceptance
- cited in PubMed and archived on PubMed Central
- yours — you keep the copyright

Submit your manuscript here:
http://www.biomedcentral.com/info/publishing_adv.asp

